

Inflammatory myofibroblastic tumour of the lung

Tarig Fadelelmoula, Momen Abdallah, Badreldin Yousif

Abstract

Inflammatory myofibroblastic tumor is an uncommon benign neoplasm, which frequently involves the lung in children and young adults; it has the tendency to be locally invasive and recurrent but rare metastasis. We present the case of a 40 year old Sudanese female with pleural inflammatory myofibroblastic tumor invading adjacent chest wall and presenting with nonspecific respiratory symptoms and signs.

Keywords: Pulmonary inflammatory pseudotumor; Myofibroblastic tumor of the lung; Plasma cell granuloma; Kappa and lambda light chain; Immunohistochemistry

Introduction

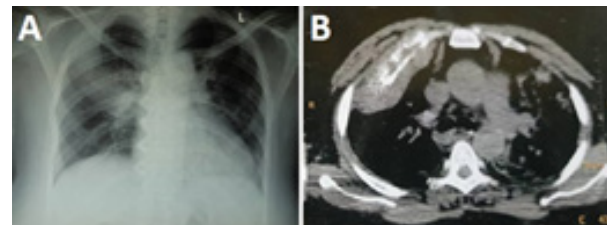
Inflammatory myofibroblastic tumor (IMT), or plasma cell granuloma, is a rare benign tumor that was first described by Bahadori and Liebow.¹ IMT frequently involves the lungs, abdominopelvic region and maxillofacial structures. The tumor mainly occurs in children and young adults.² Patients usually present with a productive cough and generally lesions are benign, with recurrence, and local blood vessels invasions, however metastasis is rare.³ Pulmonary IMT most commonly presents as a solitary thoracic nodule or clear mass on chest radiography,^{4,5} and rarely presents in the pleura.⁶ Histology reveals the proliferation of spindle cells with a prominent inflammatory infiltrate consisting of plasma cells and lymphocytes, with occasional eosinophils and neutrophils.⁷ A definitive diagnosis can be made with the immunohistochemical stain.⁸ In this paper, we present the case of a 40 year old Sudanese female with pleural IMT invading adjacent chest wall and presenting with nonspecific respiratory symptoms and signs.

Observation

We present a 40 year old female who presented with symp-

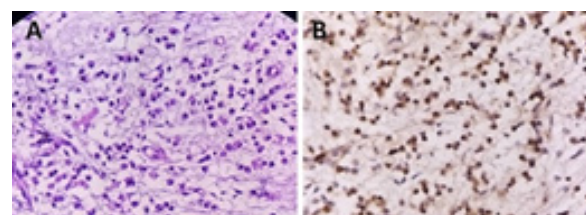
oms that had been evolving over 3 months, including cough and right chest pain. She has no associated shortness of breath or fever and her medical history was non eventful. On physical examination, she had finger clubbing and localized tenderness at the right upper chest, no significant auscultatory findings, and other systems were normal. She received analgesic for her chest pain and we planned further workup. Given the suspicion of a pneumonic process, we did a plain chest X-ray, which demonstrated opacity on the right upper lung zone. Computed tomography confirmed a peripheral mass in the upper lobe of the right lung, with local invasion and destruction of the adjacent second rib, accordingly, we performed an ultrasound guided biopsy (Figure 1A and Figure 1B).

Figure 1: (A) Chest radiography revealing opacity on the right upper lung zone on the right side. (B) Computed tomography confirming a peripheral mass in the upper lobe of the right lung, with local invasion and destruction of the second rib.



Histopathology sections showed numerous plasma cells with adjoining bone trabeculae, inflamed fibrous connective tissue, and striated muscle fibers (Figure 2A). In immunohistochemistry LCA, CD3, Kappa, and Lambda were positive, but CD20 was negative (Figure 2B). The immunohistochemistry suggested IMT and the patient were referred for thoracic surgical resection of the mass and any further management if required.

Figure 2: (A) Histological examination (hematoxylin-eosin staining) shows spindle cell proliferation with the infiltration of lymphocytes and plasma cells. (B) Immunohistochemically, neoplastic cells are focally positive for smooth muscle actin.



Dr. Tarig Fadelelmoula, Department of Respiratory Care, College of Applied Sciences, Almaarefa University, Riyadh, KSA.
Dr. Momen Abdallah, Department of Pulmonology, Al Shaab Teaching Hospital, Khartoum, Sudan. **Dr. Badreldin Yousif**, Fedail Specialized Hospital, Khartoum, Sudan.

Corresponding author: Dr. Tarig Fadelelmoula,
e-mail: ttoom@mcst.edu.sa

Discussion

IMT is a rare tumor that frequently involves the lung, and is found mainly in children and young adults. It tends to be locally invasive or recurrent and rarely metastasizes. The etiology and pathogenesis are unknown. Several theories suggested immunologic etiology. Griffin et al. reported findings suggesting that IMT is a neoplastic rather than reactive subset. Patients with IMT usually present with non-specific pulmonary features, and their chest imaging usually reveals solitary pulmonary nodules.³⁻⁵ As in our case report, histopathology sections reveal the proliferation of spindle cells with a prominent inflammatory infiltrate consisting of plasma cells and lymphocytes, with occasional eosinophils and neutrophils which highly suggestive of IMT.⁷ Immuno histochemistry markers are not specific but can support the diagnosis.⁸ The primary treatment is surgical resection; but if not respectable and/or metastatic inflammatory myofibroblastic tumor can be treated with systemic therapies, including glucocorticoids, radiotherapy, and/or chemotherapy. In our case, symptoms were nonspecific; radiology suggested invasive tumor and immunohistochemistry confirmed the diagnosis of IMT, and the patient was referred for surgical treatment.

Conclusion

IMT is rare, but frequently involves the lung, and should be in the list of the differential diagnosis for lung masses. Complete surgical removal is the primary treatment. However, when surgical excision is not possible and the metastatic inflammatory myofibroblastic tumor can be treated with systemic therapy, including glucocorticoids, radiotherapy, and/or chemotherapy.

Ethics and Consent

Written informed consent for publishing the case details and images were taken from the patient and the patient's family and an IRB exemption was obtained from the Hospital ethical committee.

Disclosure

All authors declare that they have no conflicts of interest in all steps of this case report.

Acknowledgment

The authors are thankful to the management of Al Maarefa University, Riyadh, Kingdom of Saudi Arabia, for providing necessary facilities to carry out and publish this work.

References

1. Surabhi VR, Chua S, Patel RP, et al. Inflammatory myofibroblastic tumors: Current update. *Radiol Clin North Am.* 2016;54(3):553-563.
2. Shukla PS, Mittal K. Inflammatory myofibroblastic tumor in female genital tract. *Arch Pathol Lab Med.* 2019;143(1):122-129.
3. Panagiotopoulos N, Patrini D, Gvinianidze L, et al. Inflammatory myofibroblastic tumor of the lung: A reactive lesion or a true neoplasm? *J Thorac Dis.* 2015; 7(5):908-911.
4. Yu Y, Wang X, Shi C, et al. Spectral computed tomography imaging in the differential diagnosis of lung cancer and inflammatory myofibroblastic tumor. *J Comput Assist Tomogr.* 2019; 43(2):338-344.
5. Karapolat S, Seyis KN, Ersoz S, et al. Lung image: Inflammatory myofibroblastic tumor. *Lung.* 2017; 195 (3):387-388.
6. Na YS, Park SG. Inflammatory myofibroblastic tumor of the pleura with adjacent chest wall invasion and metastasis to the kidney: A case report. *J Med Case Rep.* 2018; 12(1):253.
7. Kanagaraju V, Rai D, Alluri RV, et al. An inflammatory pseudotumor in the thoracic epidural space presenting with progressive paraplegia: A histopathological diagnosis with clinical and radiological uncertainty: Case report with literature review. *Eur Spine J.* 2016; 25 Suppl 1:75-79.
8. Werner RL, Castle JT. Inflammatory myofibroblastic tumor of the nasal cavity. *Head Neck Pathol.* 2016; 10(3):336-339.